

CLINICAL QUIZ

Eyelid Abscess with Dacryocystitis due to *Burkholderia pseudomallei*

Chee Yik Chang*

Department of Internal Medicine,
Kapit Hospital, Kapit, Sarawak, Malaysia

*Corresponding author's email:
ccyik28@gmail.com

Received: 1 May 2020

Accepted: 20 July 2020

QUESTION

A 24-year-old female complained of a 2-week history of fever and right-eye swelling. There was no ocular pain, blurring of vision, or history of prior trauma to the affected eye. On examination, she was febrile and not in respiratory distress. The right lower eyelid appeared swollen with skin erythema (Figure 1), while the visual acuity was normal. The white cell count was $14.8 \times 10^3/\mu\text{L}$ (normal range = $4 - 10 \times 10^3/\mu\text{L}$). Her liver and renal function tests were within the normal range. The abdominal ultrasonography revealed multiple splenic microabscesses, while chest radiograph was normal. Contrast-enhanced computed tomography of the orbit showed a right lower eyelid abscess with extension into the right nasolacrimal duct (Figure 2). Incision and drainage of the eyelid abscess were performed and the culture of the pus, as well as the blood, yielded *Burkholderia pseudomallei*. She received intravenous ceftazidime 2 g every 8 hours for 4 weeks, followed by oral trimethoprim-sulfamethoxazole for 20 weeks' duration. The right eyelid abscess and splenic microabscesses resolved completely post-treatment. Please interpret the figures and suggest the provisional diagnosis.

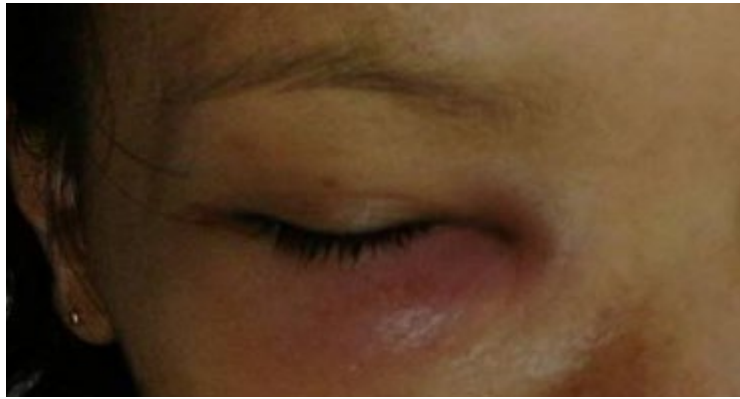


Figure 1 Swollen right lower eyelid with skin erythema

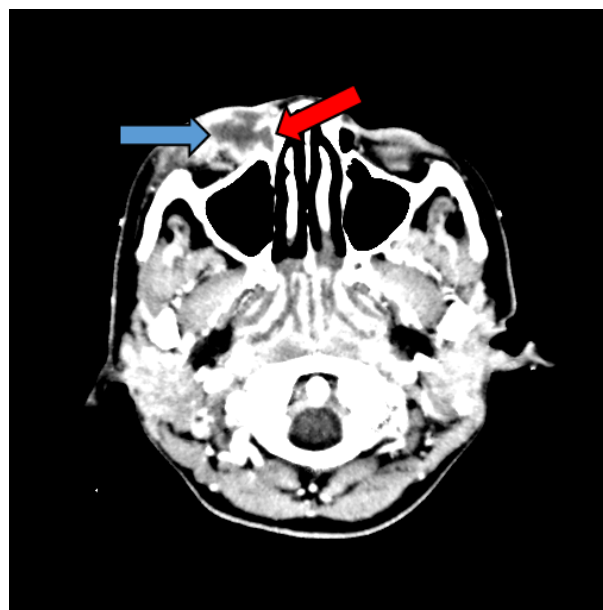


Figure 2 CT of the orbit shows right lower eyelid abscess (blue arrow) with extension into the right nasolacrimal duct (red arrow)

Please find the answer in the next issue.