

CASE REPORT

We Didn't See That Coming: Right Eye Blindness Post-Cardiac Surgery

Jayvin Kantilal Patel¹, Juin Yi Ng^{1*}, Parvin Rubon Arangulavan¹, Anas Sjahroeddin Ressang², Teik Yew David Tang¹

¹ Department of Cardiothoracic Surgery,
Queen Elizabeth Hospital II, Kota Kinabalu,
Sabah, Malaysia

² Cardiothoracic Surgery,
Department of Surgery, Faculty of Medicine,
Universiti Sultan Zainal Abidin (UNISZA),
Kuala Terengganu, Terengganu, Malaysia

*Corresponding author's email:
juinyi88@gmail.com

Received: 5 January 2022

Accepted: 4 January 2023

Published: 31 May 2023

DOI: 10.51200/bjms.v17i2.3681

Keywords: *cardiac surgery, cardiopulmonary bypass, central retinal artery occlusion, post-operative visual loss*

ABSTRACT

Postoperative visual loss (POVL) is a very rare but devastating event that can occur post-cardiac surgery. The most common cause of POVL is vascular occlusion. We present a case of a 39-year-old male with severe mixed aortic valve disease, who had to undergo double valve replacement (mechanical) due to extensive calcification. On postoperative day 7, he complained of sudden painless loss of vision in the right eye. He was diagnosed with right eye central retinal artery occlusion and was discharged home with permanent right eye blindness. Neuro-ophthalmologic complications following non-ocular surgery occur rarely. POVL occurs more likely when there are calcified heart valvular lesions, higher perioperative blood loss, hypotension, low systolic blood pressure, anaemia, hypothermia, prolonged surgery time and age >50 years old. In our case report we have encountered a couple of risk factors for ischaemia which are heavily calcified aortic and mitral valves, lower mean arterial pressure and bypass time >5 hours. Postoperative blindness can be a very serious and devastating problem with no known or established treatment. Stroke is a well-known and established complication of cardiac surgery, but central retinal artery occlusion causing loss of vision is rarely covered and explained.

INTRODUCTION

Postoperative visual loss (POVL) is a very rare but devastating event that can occur post-surgery whether it be an ocular or non-ocular surgery (Lee et al., 2006). The incidence of postoperative visual loss ranges from 0.0012 – 1% in non-ocular and non-cardiac surgery (Berg et al., 2010; Nuttall et al., 2001; Roth et al., 1996; Shen et al., 2009; Williams et al., 1995) to 0.06 – 4.5% in cardiopulmonary bypass (CPB) series (Nenekidis et al., 2012; Nuttall et al., 2001). The most common causes of POVL are vascular occlusion (65.16%), ischaemic optic neuropathies (18.48%), and cortical blindness (16.21%) (Nuzzi & Lavia, 2015). Many factors have been discussed regarding its pathogenesis for the development of POVL such as type of surgery and anaesthesia, comorbidities of a patient and intraoperative conditions but to date, its exact pathogenesis remains elusive (Berg et al., 2010; Buono et al., 2005). Here we present a rare case of POVL post-cardiac surgery.

CASE REPORT

We present a case of a 39-year-old male, ex-smoker with a body mass index (BMI) of 25 kg/m², diagnosed with severe mixed aortic valve disease, who was initially planned for elective aortic valve replacement but unfortunately had to undergo double valve replacement (mechanical). The decision to the conversion of a single valve to a double valve replacement was made in the operating theatre due to extensive calcification. He was extubated on postoperative day 1 with modest inotropes but unfortunately, he was pacing dependent with HR ranging from 30 – 40 bpm in which he required a permanent pacemaker insertion. On postoperative day 7, the patient complained of sudden painless loss of vision in the right eye upon waking up in the morning with visual acuity of only perception to light in the right eye. No history of trauma preceded the event. He was immediately referred to the ophthalmology team, and an

ophthalmic assessment revealed right eye central retinal artery occlusion (CRAO) with fundus findings as in Figure 1. Unfortunately, the visual acuity did not improve with ocular massage and acetazolamide. He had no other forms of neurological deficit. Postoperatively his recovery was complicated by a complete heart block. He was discharged home on postoperative day 21 with permanent right eye loss of vision.

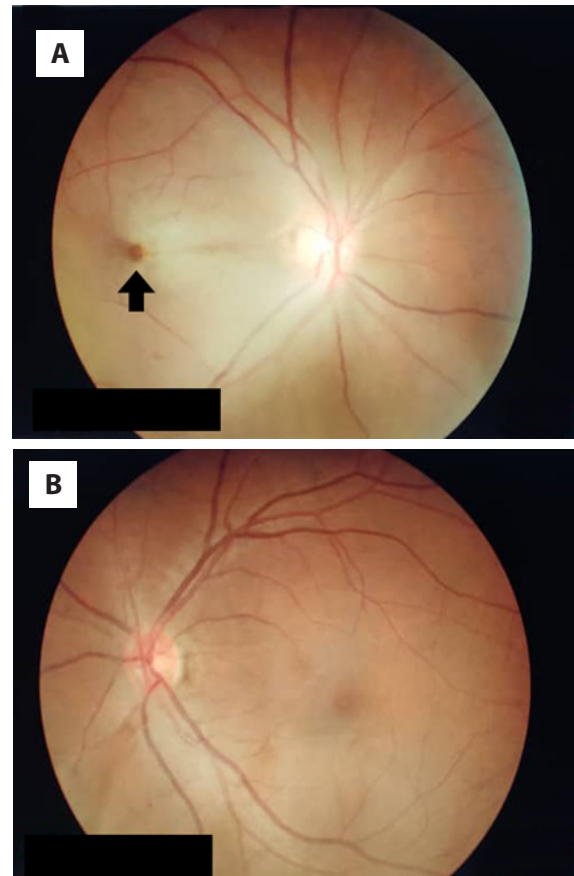


Figure 1 Fundoscopy examination of the patient's bilateral eyes, showing a cherry red spot on the macula of the right eye (A) suggestive of CRAO (black arrow). The right eye retina appears paler compared to the left eye (B), suggestive of retinal oedema of the right eye.

With a bypass time of 351 minutes and a cross-clamp time of 319 minutes, he underwent double valve replacement (mechanical) successfully despite initially being only planned for a single valve replacement (aortic). Intra-operatively his surgery was complicated

with calcification extending from the non-coronary aortic leaflet to the aorto-mitral valve curtain, all the way to the anterior mitral valve leaflet. Hence aortic and mitral valves had to be replaced (mechanical). This decision was made intra-operatively by the cardiothoracic surgeon. During cardiopulmonary bypass (CPB) an aggravated clotting time (ACT) of 488 – 629 seconds was maintained with mean arterial pressure (MAP) kept ranging from 50 – 75 mm Hg all the time with a mean MAP of 64.5 mm Hg. The patient also had his cerebral oximetry monitored as a routine monitoring which recorded a baseline reading of 66% (left) and 70% (right) with the lowest recorded reading of 50% (left) and 53% (right) for approximately 8 minutes. The estimated blood loss was 1 litre. Haematocrit (HCT) was maintained between 28 – 40% preoperatively, intraoperatively and postoperatively. The temperature was kept at 32°C during the bypass and was rewarmed back to 36°C upon coming off the bypass. The patient received 6 units of cryoprecipitate, 4 units of fresh frozen plasma, and 4 units of platelets. The total duration of operation on the bypass was 5 hours 51 minutes. He was able to wean off bypass with modest inotropic support and was transferred to the cardiothoracic intensive care unit. He was operated in a supine position throughout.

DISCUSSION

Potential neuro-ophthalmologic complications following non-ocular surgery include anterior ischaemic optic neuropathy (AION), posterior ischaemic optic neuropathy (PION), CRAO, pituitary apoplexy, and cortical blindness (Berg et al., 2010). Reports have attempted to connect anaemia, hypotension, blood loss, and other haemodynamic variables to the pathophysiology of AION and PION (Buono et al., 2005; Dilger et al., 1998; Lee et al., 2006; Myers et al., 1997; Nuzzi & Lavia, 2015). These variables occur in nearly all cases of cardiac and spine surgery and yet, AION and PION occur rarely (Shen et al., 2009). POVL occurs more

likely when there is higher perioperative blood loss (>1L) (Warner, 2006), hypotension (MAP <70, systolic blood pressure <90 mm Hg) (Berg et al., 2010), anaemia, hypothermia, prolonged surgery time (>5hours) and patient's age >50 years old (Shen et al., 2009). Perioperative anaemia has also been discussed as a cause (Hb <10 g/dL or HCT <30%) (Berg et al., 2010) with or without hypotension may precipitate the release of endogenous vasoconstrictors by the activation of the sympathetic nervous system, leading to the optic nerve and choroid ischaemia. In our case report the predisposing factors for higher risk of ischaemia are lower MAP and bypass time >5 hours.

A retrospective comparative case series in Seoul identified calcific emboli as a cause for CRAO, comprising 8% of the total emboli identified (Cho et al., 2016). There are also case reports that have identified calcified mitral and aortic valve stenosis as the primary cause of CRAO (Rumelt et al., 1999; Brockmeier et al., 1981). In the past, calcific microemboli have been shown rather conclusively to be the cause of focal retinal ischemia and infarction (Brockmeier et al., 1981; Penner & Font, 1969). In our case report, the most likely cause for postoperative blindness is a calcific embolus from either the aortic or mitral valves. This is supported by the intraoperative finding of heavily calcified valve leaflets involving both the aortic and mitral valves.

During CPB, the HCT level should be optimized and never below <25%, it should be kept as close to 35% as this would ensure enough blood flow and adequate tissue oxygenation (Nenekidis et al., 2012). Hypothermia can cause an increase in the viscosity of blood and may lead to watershed infarct of the optic nerve and this in turn also can reduce the cerebral blood flow by 6 – 7% for every degree centigrade drop in body temperature (Reuler et al., 1978). For our case report, the HCT was maintained between 28 – 40% and the temperature was kept between 32 – 36°C, and thus are not considered factors contributing to the development of CRAO.

Development of CRAO can occur in response to elevation of intraocular pressure (IOP). Elevated IOP causes reduced blood flow to the eye and in turn leads to optic nerve ischaemia (Williams et al., 1995). Perfusion pressure to the eye is determined by MAP-IOP and thus any sudden and drastic changes to the perfusion to the eye may disturb/alter the autoregulation of blood flow to the eye (Hayreh, 1997).

There may be an individual predisposition of certain patients or multiple factors that lead to a "perfect storm" of events resulting in AION or PION such as advanced age, lower minimum post-operative haemoglobin, longer bypass time, angiogram performed less than 48 hr, red blood cell (RBC) transfusion and non-RBC component transfusion (Berg et al., 2010; Nuttall et al., 2001). In this case, the combined factor of lower MAP, prolonged CPB and heavily calcified valves may have compounded to be the "perfect storm" leading to the event of CRAO.

While there are currently no established treatments available for AION, PION, CRAO, or cortical blindness, patients with pituitary apoplexy may benefit from urgent transsphenoidal decompression surgery and corticosteroid administration, and visual acuity may improve with corticosteroid administration (Berg et al., 2010).

CONCLUSION

Postoperative blindness can be a very serious and devastating problem. Stroke is a well-known and established complication of cardiac surgery and is being counselled preoperatively during consent taking. This explanation usually includes stroke involving limbs as well as poor Glasgow coma scale recovery but rarely includes total permanent blindness. Even though this incident is extremely rare but when it happens, it's very deliberating and devastating to the

patient's mental as well as physical recovery post-operatively. Not only that but from the point of medico-legal aspect also there be an implication. A more detailed consent pamphlet for patients to read in detail during their ward admission and stay for better understanding prior to actual operative consent-taking day may be beneficial in helping patients better understand the risks of POVL.

CONFLICT OF INTEREST

The authors declare that they have no conflict of interest to publish this case report or sponsorship to declare.

CONSENT

Written consent was obtained from the patient prior to the commencement of this case study. A copy of the written consent is available for review by the Chief Editor.

ACKNOWLEDGEMENTS

The authors would like to thank the Department of Cardiothoracic Anaesthesia and Perfusion and the Department of Ophthalmology for their contributions to this manuscript.

REFERENCES

- Berg, K. T., Harrison, A. R., & Lee, M. S. (2010). Perioperative visual loss in ocular and nonocular surgery. *Clinical Ophthalmology*, 4, 531 – 546. <https://doi.org/10.2147%2Fopth.s9262>
- Brockmeier, L., Adolph, R., Gustin, B., Holmes, J., & Sacks, J. (1981). Calcium emboli to the retinal artery in calcific aortic stenosis. *American Heart Journal*, 101 (1), 32 – 37. [https://doi.org/10.1016/0002-8703\(81\)90380-x](https://doi.org/10.1016/0002-8703(81)90380-x)
- Buono, L. M., & Foroozan, R. (2005). Perioperative posterior ischemic optic neuropathy: Review of the literature. *Survey of Ophthalmology*, 50 (1), 15 – 26. <https://doi.org/10.1016/j.survophthal.2004.10.005>

- Cho, K. H., Ahn, S. J., Cho, J. H., Jung, C., Han, M., Park, S. J., Park, K. H., & Woo, S. J. (2016). The characteristics of retinal emboli and its association with vascular reperfusion in retinal artery occlusion. *Investigative Ophthalmology & Visual Science*, 57 (11), 4589 – 4598. <https://doi.org/10.1167/iops.16-19887>
- Dilger, J. A., Tetzlaff, J. E., Bell, G. R., Kosmorsky, G. S., Agnor, R. C., & O'Hara, J. F., Jr. (1998). Ischaemic optic neuropathy after spinal fusion. *Canadian Journal of Anaesthesia [Journal Canadien D'anesthesie]*, 45 (1), 63 – 66. <https://doi.org/10.1007/bf03011996>
- Hayreh S. S. (1997). Anterior ischemic optic neuropathy. *Clinical Neuroscience*, 4 (5), 251 – 263.
- Lee, L. A., Roth, S., Posner, K. L., Cheney, F. W., Caplan, R. A., Newman, N. J., & Domino, K. B. (2006). The American Society of Anesthesiologists Postoperative Visual Loss Registry: Analysis of 93 spine surgery cases with postoperative visual loss. *Anesthesiology*, 105 (4), 652 – 868. <https://doi.org/10.1097/00000542-200610000-00007>
- Myers, M. A., Hamilton, S. R., Bogosian, A. J., Smith, C. H., & Wagner, T. A. (1997). Visual loss as a complication of spine surgery: A review of 37 cases. *Spine*, 22 (12), 1325 – 1329. <https://doi.org/10.1097/00007632-199706150-00009>
- Nenekidis, I., Pournaras, C. J., Tsironi, E., & Tsilimingas, N. (2012). Vision impairment during cardiac surgery and extracorporeal circulation: Current understanding and the need for further investigation. *Acta Ophthalmologica*, 90 (3), e168 – e172. <https://doi.org/10.1111/j.1755-3768.2011.02317.x>
- Nuttall, G. A., Garrity, J. A., Dearani, J. A., Abel, M. D., Schroeder, D. R., & Mullany, C. J. (2001). Risk factors for ischemic optic neuropathy after cardiopulmonary bypass: A matched case/control study. *Anesthesia and Analgesia*, 93 (6), 1410 – 1416. <https://doi.org/10.1097/00000539-200112000-00012>
- Nuzzi, R., & Lavia, C. (2015). Visual field defect after cardiac surgery: the striking role of interdisciplinary collaboration. *Case Reports in Ophthalmological Medicine*, 904528. <https://doi.org/10.1155%2F2015%2F904528>
- Penner, R., & Font, R. (1969). Retinal embolism from calcified vegetations of aortic valve: spontaneous complication of rheumatic heart. *Archives of Ophthalmology*, 81 (4), 565 – 568. <https://doi.org/10.1001/archophth.1969.00990010567018>
- Reuler, J. B. (1978). Hypothermia: Pathophysiology, clinical settings and management. *Annals of Internal Medicine*, 89 (4), 519 – 527. <https://doi.org/10.7326/0003-4819-89-4-519>
- Roth, S., Thisted, R. A., Erickson, J. P., Black, S., & Schreider, B. D. (1996). Eye injuries after nonocular surgery. A study of 60,965 anesthetics from 1988 to 1992. *Anesthesiology*, 85 (5), 1020 – 1027. <https://doi.org/10.1097/00000542-199611000-00009>
- Rumelt, S., Dorenboim, Y., & Rehany, U. (1999). Aggressive systematic treatment for central retinal artery occlusion. *American Journal of Ophthalmology*, 128 (6), 733 – 738. [https://doi.org/10.1016/s0002-9394\(99\)00359-1](https://doi.org/10.1016/s0002-9394(99)00359-1)
- Shen, Y., Drum, M., & Roth, S. (2009). The prevalence of perioperative visual loss in the United States: A 10-year study from 1996 to 2005 of spinal, orthopedic, cardiac, and general surgery. *Anesthesia and Analgesia*, 109 (5), 1534 – 1545. <https://doi.org/10.1213/ane.0b013e3181b0500b>
- Warner, M. A. (2006). Postoperative visual loss: Experts, data, and practice. *Anesthesiology*, 105 (4), 641 – 642. <https://doi.org/10.1097/00000542-200610000-00002>
- Williams, E. L., Hart, W. M., Jr, & Tempelhoff, R. (1995). Postoperative ischemic optic neuropathy. *Anesthesia and Analgesia*, 80 (5), 1018 – 1029. <https://doi.org/10.1097/00000539-199505000-00029>