

## Submucosal Lipomatosis of Caecum with Concomitant Acute Appendicitis: A Diagnostic Dilemma

Nornazirah Azizan<sup>1</sup>, Firdaus Hayati<sup>2\*</sup>, Pauline Yap<sup>2</sup>, Aishath Azna Ali<sup>3</sup>,  
Nor Haizura Abd Rani<sup>4</sup>, Fazarina Mohammed<sup>5</sup>

<sup>1</sup>Department of Pathobiology and Medical Diagnostic, Faculty of Medicine and Health Sciences, Universiti Malaysia Sabah, Sabah, Malaysia

<sup>2</sup>Department of Surgery, Faculty of Medicine and Health Sciences, Universiti Malaysia Sabah, Sabah, Malaysia

<sup>3</sup>Department of Surgery, Universiti Kebangsaan Malaysia, Kuala Lumpur, Malaysia

<sup>4</sup>Department of Pathology, Queen Elizabeth Hospital 1, Sabah, Malaysia

<sup>5</sup>Department of Pathology, Universiti Kebangsaan Malaysia, Kuala Lumpur, Malaysia

\*Corresponding author's email: firdaushayati@gmail.com

(Received: 2 June 2017; Accepted: 16 August 2017)

### ABSTRACT

Colonic lipomatosis is relatively a rare tumour of mesenchymal origin, composed of well-differentiated adipocytes interlaced by fibrous tissues. A 59-year-old lady presented with right iliac fossa pain with positive rebound tenderness, Rovsing's and obturator signs. Investigation revealed marked leucocytosis suggestive of an acute appendicitis. Diagnostic laparoscopy revealed an inflamed appendix with concomitant caecal mass suspecting of a malignancy. Laparoscopic right hemicolectomy was proceeded following oncologic resection. However, final histopathologic examination was consistent with caecal colonic lipomatosis with concomitant acute appendicitis. Hereby, dual pathologies can be elicited in an acute abdomen.

**Keywords:** acute abdomen, acute appendicitis, colonic lipomatosis.

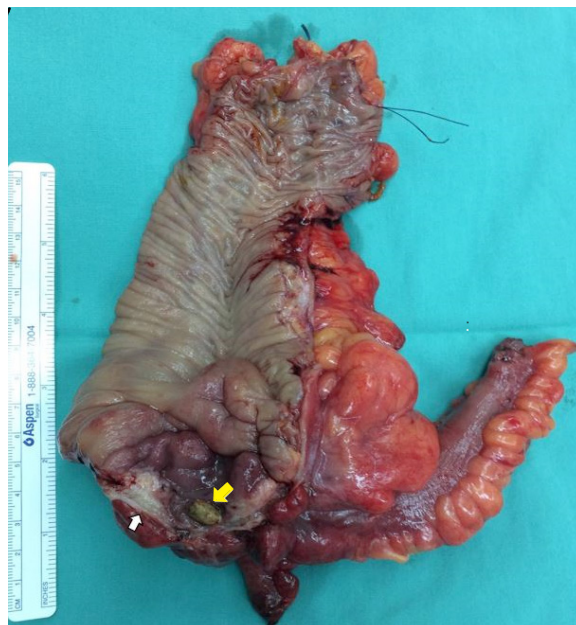
### INTRODUCTION

Colonic lipomatosis is mostly asymptomatic. It can manifest occasionally as a surgical emergency namely intussusception, obstruction, or bleeding and even masquerade malignancy.<sup>1</sup> In contrast, presented as more benign display it has been reported to mimic an acute appendicitis in surgical specimens removed for other bowel pathologies.<sup>2</sup> Majority of the cases are localized in submucosa with occasional involvement of the muscularis propria, while few are located at subserosal layer. They are mainly localized in the right-side of the colon especially the caecum. Imaging plays an important role to preoperatively diagnose this condition.<sup>3</sup>

### CASE PRESENTATION

A 59-year-old lady was referred from a private centre for acute abdomen. She presented with right iliac fossa pain associated with fever, nausea and vomiting. She denied alarming and constitutional symptoms prior to this onset. Clinically, there was rebound tenderness with positive Rovsing's and obturator signs. Biochemical investigation revealed marked leucocytosis, which was suggestive of inflammatory origin. She was posted for appendicectomy. However, peri-operative finding revealed a caecal mass. Suspecting malignancy, laparoscopic right hemicolectomy following oncologic resection was carried out.

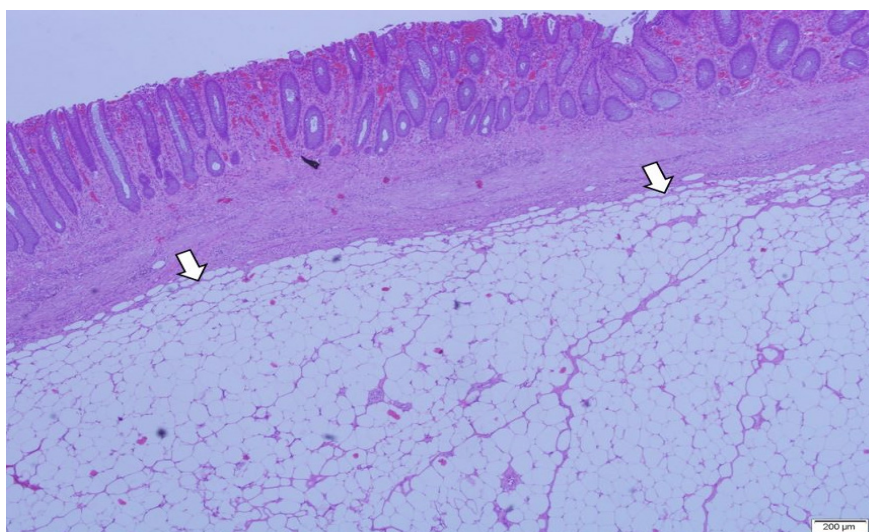
The appendix was grossly dilated, measuring 60 mm × 15 mm × 15 mm, covered by slough with presence of faecolith at the appendiceal lumen opening. There was a thickened area at the caecum, adjacent to the appendix, measuring 40 mm × 40 mm × 12 mm (Figure 1). On sectioning, it was well-defined grey-whitish firm in nature. There was no exophytic lesion arising from the colonic mucosa. There were 15 lymph nodes isolated from the mesenteric fat; the largest lymph node measures 20 mm × 15 mm × 10 mm. Patient was discharged at day 3 after obtaining a good postoperative recovery.



**Figure 1** A thickened well-defined grey-whitish area (white arrow) at the caecum with faecolith (yellow arrow) at the appendiceal lumen opening

On microscopic examination, the submucosa layer at the caecum was thickened and composed of diffusely-distributed mature univacuolated adipocytes that are relatively uniform in size and lack of cytological atypia (Figure 2). No lipoblast or atypical stromal cells were seen. The surrounding stroma showed reactive fibroblast and infiltrated by chronic inflammatory cells. Sections of the appendix

revealed a marked mucosal ulceration with dense transmural neutrophilic infiltrates. The lumen is filled with acute inflammatory exudate. The 15 lymph nodes obtained showing reactive hyperplasia without evidence of malignancy. In view of benign histology, patient was discharged from the follow-up and is symptom-free at present.



**Figure 2** The submucosa layer at the caecum is composed of diffusely-distributed mature univacuolated adipocytes (white arrows)

## **DISCUSSION**

Colonic lipomatosis is a rare entity and poses a diagnostic challenge to both surgeons and pathologists. It was first described by Hellstrom in 1906 with an incidence of less than 5% at autopsy.<sup>1</sup> In addition, it may be detected incidentally during colonoscopy as well as during open or laparoscopic surgery. Patients rarely present as acute abdomen. Only a quarter of cases with colonic lipomatosis develop symptoms. Abdominal pain, rectal bleeding, intestinal obstruction, changes of bowel habit or prolapse can be part of the presentations. Surgical interventions hence are warranted in such cases.

In contrast, stable patients are best managed conservatively after improvement of clinical parameters.<sup>2</sup> Computed tomography (CT) can be selected as a preoperative modality of diagnosis.<sup>2</sup> Features such as ovoid or pear-shaped lesion with densities of -40 to -120 Hounsfield units are typical of fatty composition to suggest of colonic lipoma in CT scan.<sup>3</sup> Other additional pathologies are required to be ruled out especially perforated diverticular disease or caecal tumour in this age group of population. Endoscopy also plays a role in preoperative diagnosis. The cushion or pillow sign (pressing forceps against the lesion results in depression or pillowing of the mass) and naked fat sign (extrusion of yellowish fat at biopsy site) are typical features in colonoscopy.<sup>3</sup> Other endoscopic imaging such as endoscopic ultrasound (EUS) has been used as well. EUS that exhibits a hyperechoic lesion originating from the submucosal layer is pathognomonic for lipoma.<sup>4</sup>

The management of symptomatic colonic lipoma can be either surgical or endoscopic techniques depending on the initial diagnostic methods. Upon endoscopy, large lesions at 2 cm diameter can safely be removed by electrosurgical snare resection

after epinephrine or saline solution injection at the base.<sup>5</sup> This precaution is to ensure a meticulous haemostasis. EUS should be utilized concomitantly to ensure that the lipomas do not extend into the muscularis propria.

In this reported case, the patient presented with acute abdomen necessitating surgical intervention as suggested clinically and biochemically. Acute appendicitis requires surgical intervention as the risk of appendicular perforation is anticipated. In view of accidental findings of caecal mass mimicking malignancy, she was opted for right hemicolectomy anticipating malignancy as the probable diagnosis. However, the histopathological diagnosis fortunately was distinct from the initial expectation.

## **CONCLUSION**

Even colonic lipomatosis is rare, physicians especially surgeons should be acknowledged of the existence of this entity. The decision to embark into surgical pathway shall be decided intelligently to avoid inevitable complications. This case highlighted the presence of dual pathologies in an acute abdomen. Being a benign nature, the prognosis of this case is excellent and the patient requires no follow-up in future.

## **CONFLICT OF INTEREST**

The authors declare that they have no competing interests.

## **CONSENTS**

Written informed consent was obtained from the patient to publish the case with its related pictures. A copy of the written consent is available for review by the Chief Editor.

## REFERENCES

1. Thakur B, Kishore S, Bhardwaj A, Kudesia S. (2014). Diffuse intestinal submucosal lipomatosis with incidental epidermal inclusion cyst of caecum clinically masquerading as carcinoma caecum. *Rare Tumors* 6 (3): 5380.
2. Sanli S, Sasani H, Darici E, Bakir B. (2015). Isolated submucosal lipomatosis of appendix mimicking acute appendicitis: Computed tomography findings. *Acta Med Anatol* 3(2): 76 – 77.
3. Katsinelos P, Chatzimavroudis G, Zavos C, Pilpilidis I, Lazaraki G, Papaziogas B, Paroutoglou G, Kountouras J, Paikos D. (2007). Cecal lipoma with pseudomalignant features: A case report and review of the literature. *World J Gastroenterol* 13 (17): 2510 – 2513.
4. Nallamothe G, Adler DG. (2011). Large Colonic Lipomas. *Gastroenterol Hepatol (NY)* 7 (7): 490 – 492.
5. Kim CY, Bandres D, Tio TL, Benjamin SB, Al-Kawas FH. (2002). Endoscopic removal of large colonic lipomas. *Gastrointest Endosc* 55 (7): 929 – 931.